

Use of the rabbit ear model in evaluating the comedogenic potential of cosmetic ingredients

WILLIAM E. MORRIS and SHIH CHAO KWAN, *Revlon Research Center, 2121 Route 27, Edison, NJ 08818.*

Received October 1981.

Synopsis

The external ear canal of the rabbit has been utilized to assess the comedogenic potential of ingredients used in the formulation of products applied to the skin. Some cosmetic raw materials have been shown to produce varying degrees of hyperkeratosis in the pilosebaceous unit of this animal model. With test results previously reported on vegetable oils, fatty acid esters, lanolins, surfactants, and other ingredients, there appear to be discrepancies in findings between investigators. The present study expands on information relating to the comedogenic potential of cosmetic components, and reevaluates the activity of several substances previously reported.

INTRODUCTION

Acne venenata, resulting from industrial exposure to chlorinated hydrocarbons, coal tars, and cutting oils, has been reported in the literature (1-4). Other external contactants included in the etiology of an "acnelike" condition have been attributed to the prolonged use of grooming aids, such as certain pomades and paraffin oils (5-6). Several cosmetics and cosmetic ingredients have been shown to produce follicular hyperkeratosis when applied to the external ear canal of rabbits (7-8). Based on animal test data and several short-term clinical studies, a human skin condition characterized by the presence of low grade, small, closed comedones, has been attributed to the prolonged use of cosmetics (7-8). Despite the admitted sensitivity and limitations of this animal model in extrapolation and application of test results to human experience (2,7-12), most of the information currently available on the comedogenic potential of topically-applied substances has been based on the "Rabbit Ear Test" (1-2,7-21).

Laboratory methods used to assess the comedogenic activity of materials applied to rabbit ears have included whole mount techniques (2,9-10), quantification of keratin after pepsin digestion of the dermis (21), microscopic examination (1-2,7-20), and a combination of clinical and microscopic evaluation (8). Because of these different methods and the lack of uniform standards for the assessment of follicular response, an accurate comparison of reported data is difficult. There do appear to be several discrepancies in test results which merit further investigation. The present study

expands on the comedogenic potential of cosmetic raw materials and reports our findings on the activity of several ingredients previously reported by others.

METHOD

Each test substance was applied once daily, five times weekly, to the external ear canal of three New Zealand rabbits. Since the goal was to achieve a uniform film over the ventral surface of the pinna, the actual amount applied was dependent on the physical form of the test material and ranged from 5-10 mg/cm². Following the fourteenth application, animals were sacrificed; several full-thickness sections of the test site and the contralateral untreated ear were dissected, formalin fixed, cut in cross section to 7 μ thickness, and stained with hematoxylin and eosin. The microscopic evaluation for comedogenic activity was based on the degree of follicular hyperkeratosis and other morphological changes in the majority of pilosebaceous units when compared to control sections, as described in Table I. In cases where comedogenic scores between

Table I
Comedogenic Grades

Comedogenic Grade	Description
0—Negative	Pilosebaceous unit normal in appearance when compared to control (untreated) ear section.
1—Slight	Slight increase in keratin content within follicle. Essentially no change in follicular epithelium.
2—Moderate	Obvious increase in follicular hyperkeratosis; some hyperplasia of follicular epithelium.
3—Moderate	Marked increase of keratin in follicular lumen resulting in a modest distention of follicles. Moderate hyperplasia of follicular epithelium.
4—Severe	Dilated follicles containing large amounts of impacted keratin. Extensive hyperplasia of follicular epithelium.
5—Severe	Widely dilated follicles, filled with packed keratin, follicular epithelial hyperplasia causing partial or total involution of sebaceous glands and ducts. Possible inflammatory changes.

animals differed by a single grade, average scores were assigned or the range of effects described. On rare occasions, when scores deviated more than one grade, the test was repeated. Unless otherwise indicated, all samples were tested undiluted.

TEST RESULTS

The comedogenic potential of a representative sampling of lanolin and lanolin derivatives (Table II) ranged from negative to severe. Little or no changes were observed in follicles exposed to the whole lanolin mixture and lanolin oil liquid fractions, with the exception of a possible slight increase in keratin when compared to untreated skin sections. Lanolin alcohol produced minimal effects consisting of some enlargement of the follicular lumen and slight hyperkeratosis (Figure 1). Applications of isopropyl lanolate (Figure 2) resulted in expanded follicles which contained large

Table II
Comedogenic Activity of Lanolins

Test Sample	Chemical Trade Name	Supplier	Comedogenic Grade
Lanolin	Super Corona Lanolin	Croda, Inc.	0
Lanolin Oil	Lanogene	Amerchol Corporation	0-1
Lanolin Oil	Lantrol	Emery Industries, Inc.	1
Lanolin Alcohol (30% in Mineral Oil)	Super Hartolan	Croda, Inc.	1-2
Isopropyl Lanolate	Amerlate-P	Amerchol Corporation	3
Lanolin Acid (50% in Mineral Oil)	Amerlate-LFA	Amerchol Corporation	4
Acetylated Lanolin Alcohol	Acetulan	Amerchol Corporation	4-5

amounts of loosely-arranged keratin with thickening of the follicular wall. Lanolin acid, despite a 50% dilution in mineral oil, induced extensive hyperplasia of follicular epithelial tissue. While some follicles became greatly distended with an accumulation of horny squamae, the majority of pilosebaceous units were completely filled with follicular epithelial cells, surrounding small, tightly packed circular keratin masses.

In the above series of samples, the most severe effects of lanolin were caused by the acetylated derivative of lanolin alcohol. Widely dilated follicles contained large whorls of impacted keratin with follicular hyperplasia extending to, and in some cases involving, sebaceous glands. An occasional intrafollicular pustule was observed.

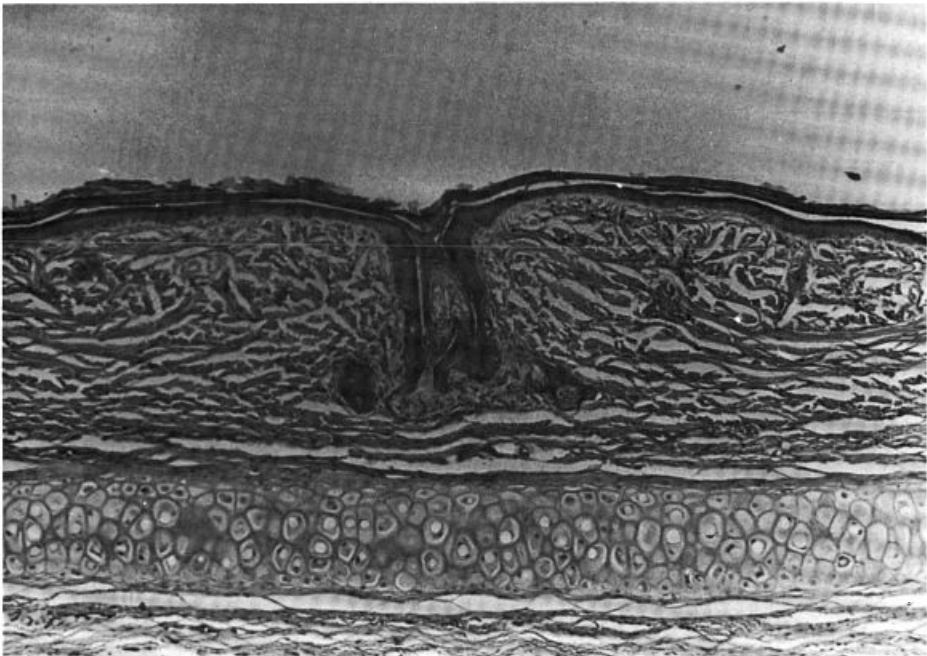


Figure 1. Comedogenic Grade 2. Obvious follicular hyperkeratosis with slight thickening of follicular epithelium caused by Lanolin Alcohol. ($\times 70$)




Figure 2. Early comedo (Grade 3) induced by isopropyl lanolate. Accumulation of keratin produced a modest distension of follicle and hyperplasia of the epithelium. ($\times 70$)

While most vegetable oils (Table III) were negative or produced slight degrees of hyperkeratosis, Grape Seed (Figure 3) and Sweet Almond oils were more reactive and resulted in enlarged hyperplastic follicles containing copious amounts of loose, horny material.

Esters of fatty acids (Table IV) evaluated in this study, with few exceptions, produced moderate to severe grades. The most comedogenic ester was isopropyl linoleate with scores reaching maximum grades (Figure 4).

The surfactants tested, at the concentrations indicated, were essentially negative (Table V).

DISCUSSION

Before discussing individual comedogenic findings, one should consider the following aspects of the test method. In assigning individual grades, the requirement for comparison to untreated test sites is emphasized, since we found, as did others (7), that a variable degree of hyperkeratosis exists in untreated animals. Our studies and others (7-8,12) have also shown that some variation in test results between animals does occur, especially at the lower, less reactive end of the comedogenic scale. These differences, however, seldom exceeded one grade unit.

After assessing the magnitude of response usually observed with the majority of cosmetic raw materials, we found it convenient to assign scores based on a six-point scale ranging from negative to severe. In our experience, a severe grade would indicate

Table III
Comedogenic Activity of Vegetable Oils

Vegetable Oil	Major Fatty Acid Triglyceride Content*			Chemical Trade Name	Supplier	Comedogenic Grade
	Oleic	Ricinoleic	Linoleic			
Olive Oil	84.0%	—	—	—	Welch, Holme & Clark	0
Avocado Oil	77.0%	—	—	—	Norda, Inc.	0
Castor Oil	—	87.0%	—	—	Baker Castor Oil Company	0-1
Corn Oil	49.0%	—	34.0%	—	Mazola—CPC International	0-1
Sesame Oil	45.0%	—	40.0%	Lipoval SES	Lipo Chemicals, Inc.	1
Safflower Oil	—	—	76.0%	—	Welch, Holme & Clark	1-2
Peach Kernel Oil	60.0%	—	30.0%	—	Norda, Inc.	2
Grape Seed Oil	31.0%	—	62.0%	—	Danco International Corp.	2-3
Sweet Almond Oil	70.0%	—	20.0%	—	Lipo Chemicals, Inc.	3

**Biology Data Book*, Second Edition, Volume 1, P. Altman & D. Dittmer, Eds. (1972).

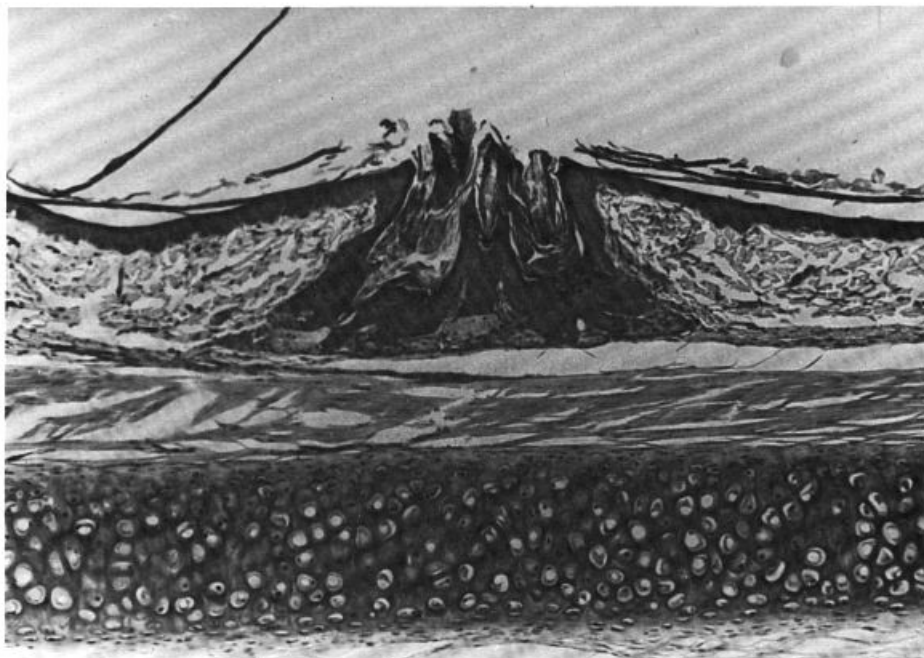


Figure 3. Comedogenic Grade 4. Enlarged follicles containing copious amounts of loosely arranged horny material resulted from applications of Grape Seed oil. ($\times 70$)

existence of large comedones resulting from applications of potent acnegens, such as coal tar. Although this scoring system is similar to others (7-8), Mills and Kligman (12), using a four-point scale to evaluate comedogenic effects of detergent products, assigned a "ten" grade to effects produced by coal tars. In agreement with Kligman and Katz (15), we found naked eye assessment to be unreliable and judged comedogenic activity solely by microscopic evaluation.

Table IV
Comedogenic Activity of Esters of Fatty Acids

Test Sample	Chemical Trade Name	Supplier	Comedogenic Grade
Decyl Oleate	Ceraphyl-140	Van Dyk & Company, Inc.	3
Isodecyl Oleate	Ceraphyl-140A	Van Dyk & Company, Inc.	1
Octyl Palmitate	Ceraphyl-368	Van Dyk & Company, Inc.	2-3
Isopropyl Palmitate		Westwood Chemical	3
Myristyl Myristate (50% in Mineral Oil)	Ceraphyl-424	Van Dyk & Company, Inc.	0-1
Isopropyl Myristate (50% in Propylene Glycol)	Wickenol 101	Wickhen Products, Inc.	3-4
Glyceryl Stearate (50% in Mineral Oil)	Myverol 18-05	Tennessee Eastman Company Kessler Division of Armour	2
Isocetyl Stearate		Chemical Corporation	0-1
Propylene Glycol Isostearate	Emerest-2389	Emery Industries, Inc.	3-4
Isopropyl Isostearate	Emerest-2310	Emery Industries, Inc.	4
Isopropyl Linoleate	Ceraphyl-1PL	Van Dyk & Company, Inc.	4-5

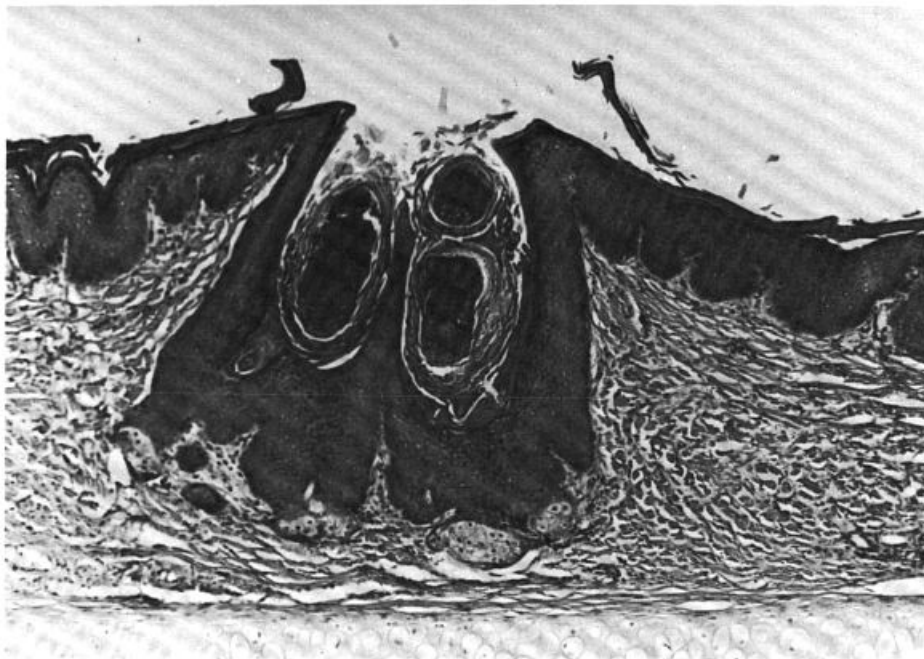


Figure 4. Comedogenic Grade 5. Isopropyl Linoleate produced large quantities of densely-packed keratin which surrounds several pustules within this dilated follicle. ($\times 70$)

In evaluating comedogenic potential, most investigators selected a two-week exposure period. To eliminate occasional questionable test results, a three-week period of applications was deemed more appropriate. In addition, our observations coincide with other investigators (15,19) who found that the follicular response approached maximum levels at this time. Since there appeared to be no consistent correlation between surface epidermal hyperplasia and morphological changes within the follicle, this criterion was ignored in the assignment of comedogenic grades.

For our investigation, we selected a cross section of lanolin ingredients widely used by the cosmetics industry. Lanolin consists of a highly complex mixture of esters of high

Table V
Comedogenic Activity of Surfactants

Test Sample	Chemical Trade Name	Supplier	Comedogenic Grade
Sodium Lauryl Sulfate (10% Aqueous)	Maprofix	Onyx Chemical Company	0
Sodium Lauryl Sulfate (5% Aqueous)	Maprofix	Onyx Chemical Company	0
Ammonium Lauryl Sulfate (10% Aqueous)	Sipon-L22	Alcolac, Inc.	0
Octoxynol-9 (50% Aqueous)	Triton X-100	Rohm & Haas Company, Inc.	0-1
Polysorbate 20 (1% Aqueous)	Tween 20	ICI Americas, Inc.	0

molecular weight aliphatic, steroid, or triterpenoid alcohols and fatty acids. Various fractions and chemical modifications of these mixtures are used in cosmetics, each with its unique physical and chemical characteristics. The comedogenic potential of these raw materials in our sampling ranged from negative to severe. Lanolin acid was more active than the whole lanolin mixture and lanolin oil liquid fractions. Acetylation of lanolin alcohol resulted in a significant increase in comedogenic potency.

Kligman and Mills (7) previously found nine of eleven lanolin samples tested to be mildly to moderately comedogenic in the rabbit ear. While they found lanolin sterols and de-waxed liquid lanolin inactive, they also report that acetylated lanolin alcohol and lanolin acid were strongly comedogenic. Fulton *et al.* (8), reporting varying degrees of activity with lanolins and their derivatives, also determined that acetylation usually resulted in increased comedogenic potency but reported lower levels of activity for lanolin acid. A report by Fulton *et al.* (8) of significant comedones resulting from applications of Lanogene, differs from our assessment of minimal activity with this ingredient obtained from the same supplier.

An evaluation of vegetable oils by Kligman and Mills (7) indicated that most had some degree of comedogenicity, usually rather low, and all were inactivated when diluted to a 25% concentration in mineral oil. In our study, test results are similar; however, the absence of activity from olive oil differs significantly from the moderate response reported by these authors. Cottonseed oil, not included in our assay, was negative in two animals treated by Kligman and Mills (7), while Kligman *et al.* (14) report this material to be mildly comedogenic but borderline when diluted with an equal part of mineral oil.

A relationship between comedogenic potential and carbon-chain length of fatty acids and corresponding triglycerides has been reported (11,14). Although vegetable oils consist of varying mixtures of triglycerides, an inspection of relative activity based on the predominating portion of these esters revealed no consistent trend with respect to chain length. Despite the documented potent activity of oleic acid (7-8,14), two oils containing 77% to 84% of its triglyceride ester demonstrated no activity. There appeared to be a trend toward increased potency in vegetable oils containing comparatively high combinations of unsaturated oleic and linoleic acid esters.

The fatty acid esters tested in this study are extensively used by the cosmetic industry as emollients or emulsifiers, often at high concentrations. With respect to the activity of these chemicals, Fulton *et al.* (8) report that although oleic and stearic acids were comedogenic, esterified products, such as butyl stearate and isopropyl isostearate, were always more potent. Our data on two derivatives of oleic acid do not support this generalization since isodecyl oleate reflected minimal comedogenic grades, and the decyl oleate ester was moderately active. With isopropyl myristate, perhaps the most widely used cosmetic emollient ester, Fulton and co-workers (8) observed severe lesions similar to those seen following applications of coal tar. Our similar findings of the high activity with this chemical conflict with the mild grades reported by Kligman and Mills (7) and Kligman and Kwong (18).

The data we report on surfactants concur with those of Kligman and Mills (7) who found these cosmetic ingredients uniformly negative. Both in their study and our laboratory observations, Triton X-100 (octoxynol-9) was assessed to be noncomedogenic at 50% concentration. Mills and Kligman (22) also show that this material

produced no effects in a human test panel when applied for six weeks under occlusive patches at 0.25% concentration. Strauss *et al.* (23), however, using the same technique, concluded that Triton X-100 appeared to be comedogenic. Our determination, and that of Kligman and Mills (7), of the noncomedogenic activity of sodium lauryl sulfate conflicts with the high scores published by Fulton *et al.* (8) on this surfactant.

This diversity in comedogenic findings among investigators using the same or similar test agents may be attributed to differences in techniques, purity of test samples, biological variations, interpretation criteria, or other unapparent factors. With a simple chemical mixture, although source and purity may differ, several dermatologists found that hydrophilic ointment (USP), for example, was noncomedogenic in both animal and human studies (7,17,22). Fulton *et al.* (8), on the other hand, report that significant comedones were produced in rabbit ears after a two-week application of a USP ointment sample and ascribe this result to the presence of sodium lauryl sulfate (1%) in the formula.

Investigators attempting the utilization of rabbit test data to predict the potential for comedogenicity in humans have emphasized several factors bearing on such comparisons. The ultrasensitivity of the rabbit follicle to respond readily to test materials has been extensively documented in published work (6-7,15,17,22-23). Differences between this animal model and the human pilosebaceous apparatus in bacterial residence, morphology, and comedo development have been outlined (9-11,15,24).

With respect to the ability of the rabbit follicle to respond quickly to many test materials, the effects of dermal irritants have not been thoroughly studied. Kligman and Katz (15) assert that hyperkeratosis of the follicular epithelium cannot be ascribed to simple irritancy and were unable to induce follicular hyperkeratosis with several strong irritants. Kligman (10) conversely states that in the first week of application it is difficult to distinguish among epidermal acanthosis, hyperkeratosis, and inflammatory changes produced by an irritant and a comedogen. He also explained that with irritants, while hyperplasia of the epidermis may be great, the follicular epithelium is usually slightly affected, and the loose, horny squame in the follicle which may accompany an irritation reaction are usually sloughed too quickly to allow comedo formation. Kligman *et al.* (14) also report that irritants usually stimulate the formation of non-adherent horny cells, while comedogenic agents cause these to stick tightly together to form a comedone. In one's observation of slight to moderate increases in follicular hyperkeratosis, confusion may exist in the interpretation of an irritant versus a comedogenic response.

CONCLUSION

The purpose of this study was to expand on data available on the comedogenic potential of cosmetic ingredients and attempt to corroborate the findings of other investigators. In some cases our test results conflict with those previously published. The discrepancies in comedogenic findings among investigators on the same or similar chemicals may be due to the use of different techniques, purity of test agents, biological variation, and other factors. Compared to established animal methods used to predict or approximate effects on human skin, the Rabbit Ear Test is a fairly new laboratory procedure. Since the comedogenic bioassay lacks standardization, we

propose that a compatible scoring system be established by researchers in this field. Photographic standards, illustrating each comedogenic grade or variation, should be required. To provide consistency of method, the exposure period as well as the quantity of test material and surface area applied should be identical between laboratories. Whenever possible, investigators should report source and purity of chemical test agents.

While the influence of test vehicle and concentration has been shown to be decisive in eliciting a response (7,12,14), much of the data available on the comedogenic potential of cosmetics is associated with the activity of ingredients which were tested undiluted or as concentrated solutions in simple chemical vehicles. In reporting findings on raw materials, there is the possibility of misinterpretation of test results and an erroneous application of data to products containing these components. To provide additional information that would be of value to those in product development, the relationship between the comedogenic activity of these chemicals at use concentrations and as combinations in various product bases should be investigated.

Recent work by Mills and Kligman (25) has shown that substances which are strongly comedogenic in the rabbit ear were capable of inducing comedones in a human model. The subjects selected for the study were young, adult black men with prominent follicular orifices at the test site. To further evaluate the relevance of the animal model to the human, the susceptibility of skin types in the general population would be useful.

In summary, the rabbit may prove to be an interesting model for the study of the comedogenic effects of topically applied materials, provided test results of a standardized method are reproducible among laboratories. If the rabbit ear model is shown to be predictive of human experience, evaluation of ingredients via this model may be useful in the formulation of non-comedogenic consumer products. Ultimately, the final product composition must be evaluated.

ACKNOWLEDGMENTS

The authors wish to thank Messrs. J. DiNardo and A. Schmidt for their technical assistance, and Mrs. V. Schutz for her contribution in preparation of the manuscript.

REFERENCES

- (1) E. M. Adams, D. D. Irish, H. C. Spencer, and V. K. Rowe, The response of rabbit skin to compounds reported to have caused acneform dermatitis, *Industrial Medicine*, Industrial Hygiene Section, 2, 1, 1-4 (1941).
- (2) G. W. Hambrick, The effect of substituted naphthalenes on the pilosebaceous apparatus of rabbit and man, *J. Invest. Dermatol.*, 28, 89-102 (1957).
- (3) W. B. Shelley and A. M. Kligman, The experimental production of acne by penta- and hexachloronaphthalenes, *AMA Arch. Dermatol.*, 75, 689-695 (1957).
- (4) J. Bleiberg, M. Wallen, R. Brodtkin, and I. L. Applebaum, Industrially acquired porphyria, *Arch. Dermatol.*, 89, 793-797 (1964).
- (5) C. Berlin, Acne comedo in children due to paraffin oil applied on the head, *AMA Arch. Dermatol. & Syphilol.*, 69, 683-687 (1954).
- (6) G. Plewig, J. E. Fulton, and A. M. Kligman, Pomade acne, *Arch. Dermatol.*, 101, 580-584 (1970).
- (7) A. M. Kligman and O. H. Mills, Acne Cosmetica, *Arch. Dermatol.*, 106, 843 (1972).

- (8) J. E. Fulton, S. Bradley, A. Aquendex, and T. Black, Noncomedogenic cosmetics, *Cutis*, **17**, 344-351 (1976).
- (9) G. W. Hambrick and H. Blank, A microanatomical study of the response of the pilosebaceous apparatus of the rabbit's ear canal, *J. Invest. Dermatol.*, **26**, 185-198 (1956).
- (10) A. M. Kligman, Pathogenesis of acne vulgaris. II. Histopathology of comedones induced in the rabbit ear by human sebum, *Arch. Dermatol.*, **98**, 58-66 (1968).
- (11) P. Kanaar, Follicular-keratogenic properties of fatty acids in the external ear canal of the rabbit, *Dermatologica*, **142**, 14-22 (1971).
- (12) O. H. Mills and A. M. Kligman, Acne detergicams, *Arch. Dermatol.*, **111**, 65-68 (1975).
- (13) P. C. Woo-Sam, The effect of vitamin A acid on experimentally induced comedones: An electron microscope study, *Brit. J. Dermatol.*, **100**, 267-276 (1979).
- (14) A. M. Kligman, V. R. Wheatley, and O. H. Mills, Comedogenicity of human sebum, *Arch. Dermatol.*, **102** (1970).
- (15) A. M. Kligman and A. G. Katz, Pathogenesis of acne vulgaris. I. Comedogenic properties of human sebum in external ear canal of the rabbit, *Arch. Dermatol.*, **98**, 53-66 (1968).
- (16) O. H. Mills and A. M. Kligman, Assay of comedolytic agents in the rabbit ear, in *Animal Models in Dermatology*, H. Maibach, Ed. (Churchill Livingstone, N.Y., 1975), pp 176-183.
- (17) O. H. Mills, M. Porte, and A. M. Kligman, Enhancement of comedogenic substances by ultraviolet radiation, *Brit. J. Dermatol.*, **98**, 145-150 (1978).
- (18) A. M. Kligman and T. Kwong, An improved rabbit ear model for assessing comedogenic substances, *Brit. J. Dermatol.*, **100**, 699-702 (1979).
- (19) P. C. Woo-Sam, Cohesion of horny cells during comedo formation—an electron microscope study, *Brit. J. Dermatol.*, **97**, 609-615 (1977).
- (20) P. C. Woo-Sam, A quantitative study of membrane coating granules in follicles undergoing experimental comedo formation, *Brit. J. Dermatol.*, **99**, 387-394 (1978).
- (21) E. L. Jones and H. Krizek, A technic for testing acnegenic potency in rabbits, applied to the potent acnegen, 2,3,7,8-tetrachloro-dibenzo-P-Dioxin, *J. Invest. Dermatol.*, **39**, 511-517 (1962).
- (22) O. H. Mills and A. M. Kligman, Is sulphur helpful or harmful in acne vulgaris?, *Brit. J. Dermatol.*, **86**, 420 (1972).
- (23) J. S. Strauss, P. H. Goldman, S. Nacht, and E. H. Gans, A re-examination of the potential comedogenicity of sulfur, *Arch. Dermatol.*, **114**, 1340-1342 (1978).
- (24) S. B. Frank, Is the rabbit ear model, in its present state, prophetic of acnegenicity?, *J. Amer. Acad. Dermatol.*, **6**, 3 (1982).
- (25) O. H. Mills and A. Kligman, A human model for assessing comedogenic substances, *Arch. Dermatol.*, **118**, 903-905 (1982).